

Clinical report

B-mode video ultrasonography for detecting aspiration : two case studies

Yuka Miura^{1) 2)}, Gojiro Nakagami¹⁾, Haruka Tohara³⁾, Ryoko Murayama⁴⁾
Hiroshi Noguchi⁵⁾, Taketoshi Mori⁵⁾, Hiromi Sanada¹⁾

¹⁾Department of Gerontological Nursing / Wound Care Management, Division of Health and Nursing, Graduate School of Medicine, The University of Tokyo

²⁾Japan Society for the Promotion of Science

³⁾Gerodontology and Oral Rehabilitation, Department of Gerontology and Gerodontology, Graduate School of Medical and Dental Sciences, Tokyo Medical and Dental University

⁴⁾Department of Advanced Nursing Technology, Graduate School of Medicine, The University of Tokyo

⁵⁾Department of Life Support Technology (Molten) , Graduate School of Medicine, The University of Tokyo

Key words

aspiration pneumonia, deglutition, deglutition disorders, videofluoroscopic swallowing study, ultrasound

Abstract

Aspiration is the passage of food or liquid through the vocal folds and into the larynx or lower respiratory tract. Silent aspiration, which does not produce a reflective cough or other overt cues, is associated with an increased risk of aspiration pneumonia, which is a common cause of death among Japanese elderly people. Therefore detecting aspiration by imaging method is an important part of preventing aspiration pneumonia. We experienced two dysphagia elderly patients with aspiration during the videofluoroscopy (VF) examination. One of the patients was diagnosed as silent aspiration. We simultaneously performed B-mode video ultrasonography (BV-US) with VF examination for both patients. BV-US revealed the vocal folds as a hyperechoic object that vibrated during speaking, so we used this region as a landmark during our examination. We used honey-thick barium liquid and nectar-thick barium liquid for the VF examination. We found that aspiration, which occurred when the bolus passed below the vocal folds, could be observed in BV-US images. An aspirated bolus appeared as a hyperechoic line along the tracheal wall in both patients. To our knowledge, this is the first report that a bolus in the tracheal inside can be observed with BV-US. This new finding suggests that BV-US has potential for detecting aspiration during swallowing.

Introduction

Pneumonia is the third leading cause of death in Japan. Aspiration pneumonia accounts for 90

% of pneumonia deaths, which predominantly occur in elderly people¹⁾. Aspiration is defined as the passage of food or liquid through the vocal

folds, and into the larynx or lower respiratory tract²). Repeated aspiration may cause bacteria within food or saliva to accumulate in the lungs, resulting in aspiration pneumonia³). Silent aspiration, which does not produce a reflective cough or other overt cues, is associated with an increased risk of aspiration pneumonia because it is sometimes overlooked by non-imaging bedside assessments⁴⁾⁵⁾. Therefore, early detection of aspiration, including silent aspiration, by imaging technique is necessary to reduce the risk of aspiration pneumonia.

Videofluoroscopy (VF) and videoendoscopy (VE) are useful methods for assessing dysphagia⁶⁾⁷⁾. For instance, silent aspiration can only be detected using these imaging techniques. However, both technologies have limitations. VF exposes patients to radiation and requires the use of a contrast medium, such as barium sulfate⁸⁾. Although VE examination can be conducted at a patient's bedside using their regular food, this method requires the insertion of an endoscope through the nose into the larynx.

Several studies have revealed that B-mode video ultrasonography (BV-US) can be used to track the movement of the tongue and hyoid bone during swallowing⁹⁾¹⁰⁾. It is possible to identify the tongue and hyoid bone using this technique because these regions are surrounded by tissue with differing acoustic impedances. However, this technique has not yet been used to observe the passage of food or liquid through the vocal folds, and so whether BV-US can be used to detect aspiration is unknown. BV-US is noninvasive, and so it is a desirable method for detecting the presence of an aspirated bolus in the trachea of an individual, which ultimately can lead to appropriate swallowing care. We will be able to prevent aspiration by modifying food and liquid viscosity based on the result of BV-US examination. In the current study, we present ultrasonographic findings of aspiration during swallowing in two patients, and consider the possibilities of using this method for assessment of dysphagia.

Methods

1. Research design and participants

Two case studies were conducted from July to August 2012. All data were collected at the dysphagia outpatient clinic of a general hospital in Chiba prefecture, Japan. We recruited two patients who underwent VF examination in the hospital. The study protocol was approved by the Ethical Committee of the Graduate School of Medicine at The University of Tokyo (#3260). We obtained written informed consent from all participants.

2. BV-US examinations

Both patients were examined using VF while they sat in an upright position in a wheelchair. The wheelchair had a backrest that enabled manual body angulation. We did not fix the head and neck positions of the participants, as we wanted them to be able to swallow in a posture that felt comfortable. First, a transducer for the longitudinal scan was placed above the vocal folds (Fig. 1A). Then, each patient was asked to speak. We detected the vibrations of the vocal folds on the display screen, which we used as landmarks for movement during swallowing (Fig. 1B). We could detect the skin observed as the top layer. The upper tracheal wall was observed as a hyperechoic line below the cricoid cartilage, which was observed as a hypoechoic area. While the VF examination was performed, we used BV-US to track swallowing movement around the vocal folds. The operator held the transducer in place during swallowing and ensured that the swallowing movements were not disturbed. For the BV-US examination, we used M-turbo ultrasound system (Sonosite, Bothwell, WA, USA) equipped with a linear (6-15 MHz) transducer. The gain and dynamic range were adjusted according to the quality of the image. The image depth was set at 4 cm to bring the trachea into the focal point.

Results

Case 1

A 60-year-old man was admitted to the hospital to be treated for cerebral infarction. During his stay at the hospital he received enteral

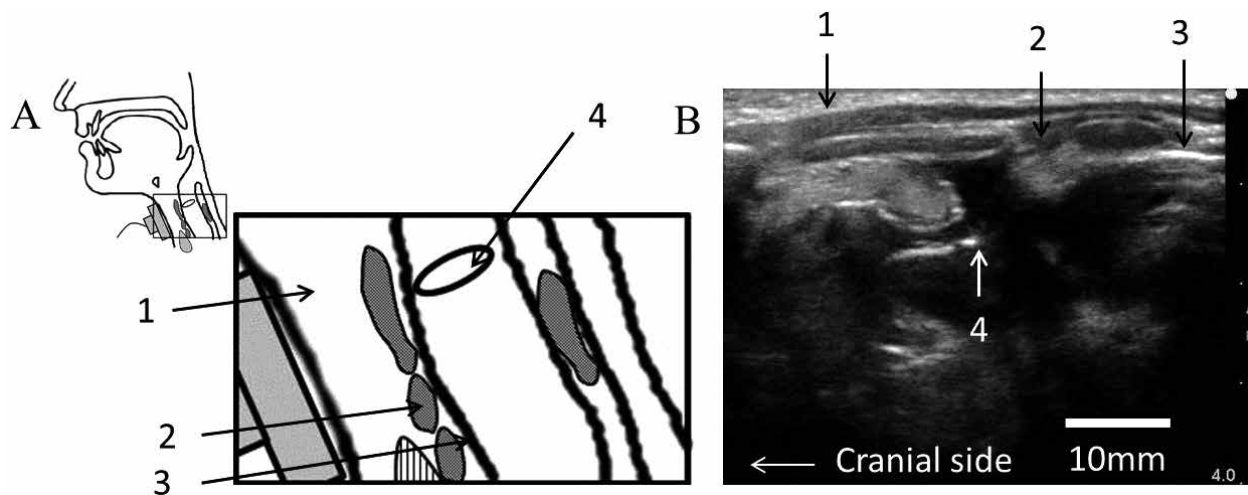


Figure. 1 Anatomy of the larynx (A) and BV-US image of the larynx (B)

Figure Legends

Fig. 1 Anatomy of the larynx (A) and BV-US image of the larynx (B)

The transducer is placed so that it can detect the vocal folds as a landmark (A).

The top layer represents skin (1), the hypoechoic area represents cricoid cartilage (2), the hyperechoic line below the cricoid cartilage represents tracheal wall (3), and the hyperechoic objects in the trachea represent vibrating vocal folds (4).

nutrition via a nasogastric tube. We used VF to evaluate his ability to engage in partial oral feeding.

The participant was asked to swallow honey-thick barium liquid from a cup while his head was oriented up in a 90-degree position. VF analysis revealed that part of the bolus passed through the vocal folds and entered the trachea (Fig. 2A, C, E). The participant did not exhibit any cough symptoms, so he was diagnosed as having silent aspiration. To reduce his risk of aspiration pneumonia, we recommended that he continue to use a nasogastric tube for feeding. We also suggested that he engage in exercises to increase his range of motion and practice intensive oral maintenance.

Before he began to swallow the bolus, the BV-US image displayed his vocal folds as a vibrating hyperechoic object (Fig. 2B). The vocal folds disappeared from the BV-US display during the swallowing because of the laryngeal elevation. The upper tracheal wall appeared as a hyperechoic line. The lumen appeared as a dark shade of gray because it contains a lot of air, which causes high attenuation. When the swallowing reflex occurred, a hyperechoic line appeared along the tracheal wall (Fig. 2D). The line then moved in an inferior direction and disappeared

from the tracheal area (Fig. 2F).

Case 2

A 76-year-old man underwent VF examination to determine his optimal fluid viscosity for swallowing. He had a history of Parkinson's disease and cerebral infarction. He reported that his facial paralysis had recently become more severe.

The participant was asked to swallow nectar-thick barium liquid with his head oriented up in a 90-degree position. VF analysis revealed a slight black shadow in the trachea prior to the swallowing reflex (Fig. 3A). When the swallowing reflex occurred most of the bolus passed through the esophagus, although a portion of the bolus entered the lower trachea (Fig. 3C). The remaining part of the bolus stayed within the trachea after swallowing (Fig. 3E). The patient presented with a cough after swallowing. Consequently, we recommended that he use food thickener with a higher viscosity to reduce the risk of aspiration. Before swallowing, the BV-US image displayed his vocal folds as a vibrating hyperechoic object. The lumen of the trachea appeared as a dark shade of gray, and a hyperechoic object was observed in the tracheal area (Fig. 3B). When the swallowing reflex occurred, a hyperechoic line immediately appeared in the

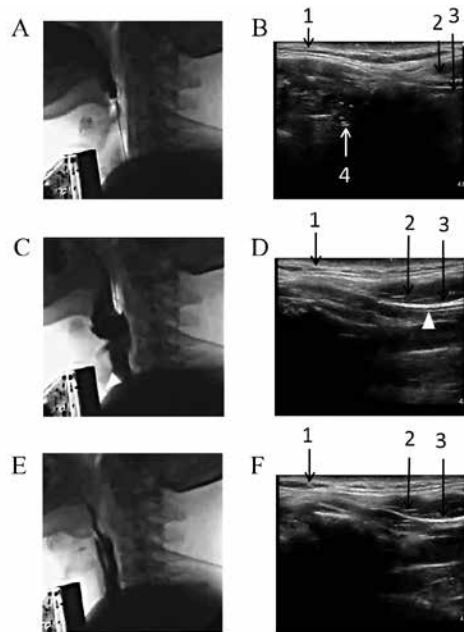


Figure.2 Images of a 60-year-old man of VF and BV-US

Fig. 2 Images of a 60-year-old man of VF and BV-US

The serial numbers represent the same organs as figure 1. Before swallowing there was no bolus in the trachea (A). Before swallowing, the vibrating vocal folds appear as a hyperechoic object in the BV-US image. The upper tracheal wall appeared as a predominantly hyperechoic line (B). The honey-thick barium liquid in the trachea is represented as a black narrow shadow in the VF image (white arrowhead) (C). The aspirated liquid appeared as a hyperechoic line in the BV-US image along the upper tracheal wall (white arrowhead) (D). After the swallowing, the barium liquid disappeared from the trachea in the VF image (E). The hyperechoic line along the upper tracheal wall also disappeared from the BV-US image after swallowing (F).

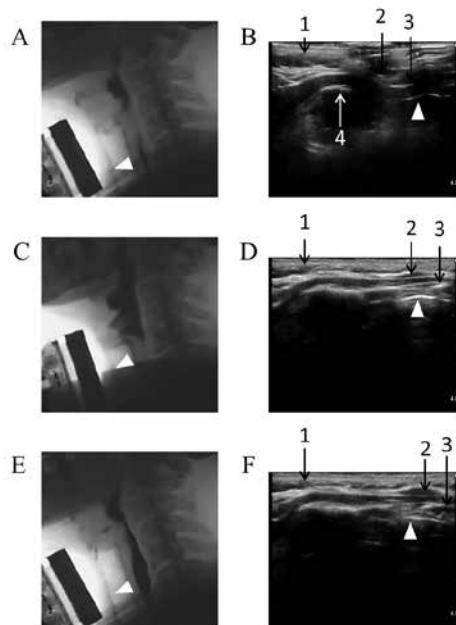


Figure.3 Images of a 76-year-old man of VF and BV-US

Fig. 3 Images of a 76-year-old man of VF and BV-US

The serial numbers represent the same organs as figure 1. Before swallowing, the remaining aspirated bolus appeared as a slight black shadow in the VF image (white arrowhead) (A). The vocal folds appear as a hyperechoic object in the BV-US image. The upper tracheal wall was observed as a predominantly hyperechoic line. The remaining aspirated bolus was observed as a hyperechoic line in the BV-US image (white arrowhead) (B). When the swallowing reflex occurred, additional aspirated nectar-thick barium liquid was observed in the trachea in the VF image (C). The aspirated liquid appeared as a hyperechoic line along the tracheal wall (D). The remained aspirated barium liquid is shown in the lower region of the VF image (E). A corresponding hyperechoic line is seen in the lower region of the BV-US image (F).

tracheal area and then remained in an inferior direction (Fig. 3D, F). The vocal folds disappeared from the BV-US display during the swallowing because of the laryngeal elevation as it is for case 1.

Discussion

In this study, we report our findings from two cases in which we used BV-US to identify the passage of a bolus through the vocal folds. Aspirated bolus in the trachea was observed as a hyperechoic line moving along the trachea wall in both patients by the BV-US examination. To our knowledge, this is the first time this technique has been used to detect aspiration.

Generally speaking, BV-US is not an obvious choice for observing aspiration because the air in the trachea causes high ultrasound attenuation, making it difficult to discern the anatomy involved. As a result, published ultrasound images of the trachea during swallowing are scarce, although several reports have included BV-US imaging of the bolus in the oral cavity during the different phases of oral and pharyngeal swallowing¹¹⁻¹³). There are some amounts of air present in the oral cavity and the pharynx, so we focused on the region around the vocal folds when imaging the aspirated bolus, as ultrasound attenuation by air would be minimal in this location. BV-US observation of the vocal folds indicated that the trachea was sufficiently narrow at the vocal folds to permit visualization of the bolus in the trachea¹⁴). As expected, we found reduced ultrasound attenuation by air around the vocal folds, enabling us to obtain good visualization of the bolus in the trachea. Barium sulfate, which contains some air bubbles, also facilitated BV-US visualization because the difference between the acoustic impedance of the bubbles and the surrounding liquid was high. As a result, we were able to detect aspiration, which was indicated by a hyperechoic line moving along the tracheal wall. We were able to confirm that the observed hyperechoic objects were equivalent to the aspirated bolus by comparing the BV-US images to the simultaneously obtained VF images.

Several non-imaging based tests are used to

screen for dysphagia. They include the water swallowing test¹⁵), the food test¹⁶), and the repetitive saliva swallowing test¹⁷). These tests are convenient because they do not require any special equipment. However, silent aspiration may not be detected because these tests use coughing as an indicator of aspiration. Recently, some researchers indicated that the cough test which takes induced cough reflex by citric acid particle inhalation as a surrogate indicator of silent aspiration could be a useful screening test^{18) 19}). Although the cough test has high sensitivity and specificity, it does not enable clinicians to acquire images of the aspirated bolus. In other words, the cough test does not provide clinicians with enough information to determine what bolus viscosity would reduce the risk of the aspiration. In the current study, we used BV-US to detect silent aspiration, which appeared as a moving hyperechoic line in a series of sequential images. We were also able to detect aspiration with fluids of differing viscosities (honey-thick liquid and nectar-thick liquid). A bedside imaging technique for detecting aspiration, including silent aspiration, will be useful for developing methods to prevent aspiration pneumonia. It is possible that, with BV-US imaging, clinicians will be able to detect aspiration earlier and thus modify food viscosity appropriately, thus reducing the risk of aspiration pneumonia.

BV-US offers several advantages over VF. First, BV-US allows for the use of a patients' regular diet. We used barium sulfate to simultaneously take BV-US and VF images. Air in the barium sulfate facilitated BV-US visualization, however previous studies have reported that liquid without barium can also be detected in the oral cavity^{11) 13}). In future studies we plan to examine the possibility of imaging with different liquids using VE without barium sulfate. Secondly, BV-US does not expose patients to ionizing radiation, thus it is more appropriate as a bedside examination method. BV-US swallowing examinations may be especially useful for bedridden patients who may be difficult to transport to a fluoroscopy room. In other words, patients can undergo a BV-US examination to detect as-

piration in their room without interrupting their regular feeding routine.

This case study suggests that the new non-invasive detection method based on BV-US will allow clinicians to provide daily appropriate swallowing care. Clinicians will be able to detect silent aspirations that have been overlooked by bedside screening tests and aspirations that have been overlooked by lack of timely detection methods. We will try to investigate the application of this technique to the dysphagia patients with a variety of body types because quality of US observation largely depends on thickness of the fatty layer where high ultrasound attenuation occurs and therefore visualization of the bolus within the trachea would be obscured.

Conclusion

We have demonstrated that aspiration during swallowing can be detected using the simple and non-invasive BV-US technique. We anticipate that our report will be of value in guiding medical professionals, such as clinicians and nurses, in the use of this tool for the bedside assessments of patient swallowing function.

Acknowledgements

This work was funded by a Grant-in-aid for Challenging Exploratory Research from the Japan Society for the Promotion of Science to H. Sanada (No. 23659999). The funding organizations had no role in the design and conduct of the study or in the preparation, review, and approval of the manuscript. We thank the director of the Katsuragi hospital, Dr. Mutsumi Ohue, who provided advice and assistance during the period of the study. We would also like to express our sincere thanks to all of the patients with dysphagia who participated in this study and to the clinical staff who supported the data collection.

Conflict of Interest

All authors declare no conflict of interest.

References

- 1) Ministry Of Health, Labour And Welfare : vital statistics, [on-line <http://www.mhlw.go.jp/toukei/saikin/hw/jinkou/geppo/nengai11/kekka03.html>], 20. 10. 2013
- 2) Rosenbek JC, Robbins JA, Roecker EB, et al. : A penetration-aspiration scale, *Dysphagia*, 11(2), 93–98, 1996
- 3) Ramsey D, Smithard D, Kalra L : Silent aspiration: what do we know?, *Dysphagia*, 20(3), 218–225, 2005
- 4) Kikuchi R, Watabe N, Konno T, et al. : High incidence of silent aspiration in elderly patients with community-acquired pneumonia, *Am J Respir Crit Care Med*, 150(1), 251–253, 1994
- 5) Pikus L, Levine MS, Yang YX, et al. : Videofluoroscopic studies of swallowing dysfunction and the relative risk of pneumonia, *AJR Am J Roentgenol*, 180(6), 1613–1616, 2003
- 6) Wu CH, Hsiao TY, Chen JC, et al. : Evaluation of swallowing safety with fiberoptic endoscope: comparison with videofluoroscopic technique, *Laryngoscope*, 107(3), 396–401, 1997
- 7) Smith CH, Logemann JA, Colangelo LA, et al. : Incidence and patient characteristics associated with silent aspiration in the acute care setting, *Dysphagia*, 14(1), 1–7, 1999
- 8) Bours GJ, Speyer R, Lemmens J, et al. : Bedside screening tests vs. videofluoroscopy or fiberoptic endoscopic evaluation of swallowing to detect dysphagia in patients with neurological disorders: systematic review, *J Adv Nurs*, 65(3), 477–493, 2009
- 9) Cerro P, Diotallevi P, Fanucci E, et al. : Echography of the oral phase of deglutition, *Radiol Med*, 79(1–2), 59–64, 1990
- 10) Yabunaka K, Sanada H, Sanada S, et al. : Sonographic assessment of hyoid bone movement during swallowing: a study of normal adults with advancing age, *Radiol Phys Technol*, 4(1), 73–77, 2011
- 11) Casas MJ, Seo AH, Kenny DJ : Sonographic examination of the oral phase of swallowing: bolus image enhancement, *J Clin Ultrasound*, 30(2), 83–87, 2002
- 12) Geddes DT, Chadwick LM, Kent JC, et al. : Ultrasound imaging of infant swallowing during breast-feeding, *Dysphagia*, 25(3), 183–191, 2010

- 13) Tamburrini S, Solazzo A, Sagnelli A, et al. : Amyotrophic lateral sclerosis: sonographic evaluation of dysphagia, *Radiol Med*, 115(5), 784–793, 2010
- 14) Hu Q, Zhu SY, Luo F, et al. : High-frequency sonographic measurements of true and false vocal cords, *J Ultrasound Med*, 29(7), 1023–1030, 2010
- 15) Wu MC, Chang YC, Wang TG, et al. : Evaluating swallowing dysfunction using a 100-ml water swallowing test, *Dysphagia*, 19(1), 43–47, 2004
- 16) Tohara H, Saitoh E, Mays KA, et al. : Three tests for predicting aspiration without video-fluorography, *Dysphagia*, 18(2), 126–134, 2003
- 17) Oguchi K, Saitoh E, Mizuno M, et al. : The repetitive saliva swallowing test (RSST) as a screening test of functional dysphagia (1) normal values of RSST, *Jpn J Rehabil Med*, 37(6), 383–388, 2000 (in Japanese)
- 18) Wakasugi Y, Tohara H, Hattori F, et al. : Screening test for silent aspiration at the bedside, *Dysphagia*, 23(4), 364–370, 2008
- 19) Sato M, Tohara H, Iida T, et al. : Simplified cough test for screening silent aspiration, *Arch Phys Med Rehabil*, 93(11), 1982–1986, 2012

Bモード超音波検査による誤嚥所見の検出方法の提案：2症例の報告

三浦 由佳^{1) 2)}, 仲上 豪二郎¹⁾, 戸原 玄³⁾, 村上 陵子⁴⁾
野口 博史⁵⁾, 森 武俊⁵⁾, 真田 弘美¹⁾

¹⁾ 東京大学大学院医学系研究科健康科学・看護学専攻 老年看護学／創傷看護学分野

²⁾ 独立行政法人日本学術振興会

³⁾ 東京医科歯科大学大学院医歯学総合研究科老化制御学系専攻高齢者歯科学分野

⁴⁾ 東京大学大学院医学系研究科社会連携学講座アドバンストナーシングテクノロジー

⁵⁾ 東京大学大学院医学系研究科ライフサポート技術開発学(モルテン)寄附講座

キーワード

誤嚥性肺炎, 嚥下, 嚥下障害, 嚥下造影検査, 超音波検査

要 旨

誤嚥とは食物や水分が声帯を超え喉頭以下の下気道に流入することである。特にむせ等の臨床的兆候を生じない不顕性誤嚥は本邦の高齢者の死因の多くを占める誤嚥性肺炎のリスク要因となっている。そのため誤嚥性肺炎を予防するには誤嚥を画像検査によって検出することが重要である。今回嚥下造影検査(VF)にて誤嚥が検出された2名の高齢者についてBモード超音波検査(BV-US)を同時に施行した症例を報告する。うち1名は不顕性誤嚥の患者であった。BV-US画像において声帯は発生時に振動する高輝度な物質として描出されており検査時にランドマークとして用いた。検査食にはハチミツ状およびネクター状の粘度のバリウム溶液を用いた。BV-USにおいて嚥下物質が声帯を超える状態である誤嚥を観察することが可能であり、誤嚥物質は気管壁に沿う高輝度な線状所見として観察された。本研究はBV-USにおいて気管内の誤嚥物質を観察した初の研究である。この結果BV-USにて嚥下時の誤嚥を観察できる可能性が示唆された。